**13 – ORIGINAL ARTICLE**
**CLINICAL INVESTIGATION**

# The application of percutaneous lysis of epidural adhesions in patients with failed back surgery syndrome[1]

## A aplicação da lise percutânea de aderências epidurais em pacientes com síndrome pós-laminectomia

**He Chun-jing[I], Nie Hao-xiong[II], Ni jia-xiang[III]**

[I]MD, Department of Anesthesiology, Guizhou Provincial People's Hospital□Guiyang□China. Acquisition, analysis and interpretation of data.
[II]MD, Department of Anesthesiology, Guizhou Provincial People's Hospital□Guiyang□China China. Acquisition and analysis of data.
[III]MD, Department of Pain, Xuanwu Hospital, Capital Medical University, Xuanwu District, Beijing, China. Conception and design.

**ABSTRACT**

**PURPOSE**: To investigate the efficacy and the feasibility of application of percutaneous lysis of epidural adhesions in failed back surgery syndrome (FBSS) using a stiff type guide wire and 4F vascular catheter.

**METHODS**: Ninety two patients with FBSS were randomly divided into two groups, the control group (treated by injection dexamethasone only) and percutaneous lysis of epidural adhesions group. Visual analog scale scores (VAS) and therapeutic evaluation were observed in the preoperative, seven days postoperative, one month and six months postoperative.

**RESULTS**: VAS scores for pain were significantly reduced in both groups at seven days. The VAS scores were in controlled group at one month, six months was significantly higher than that in epidural lysis group. However, there was no statistical difference in VAS scores of one month and six months when respectively compared to that of before operation in controlled group. Patients on epidural lysis reported clinical effectiveness rate was 50%. Patients on control was 5.26%, there was a statistical difference between two groups.

**CONCLUSION**: Percutaneous lysis of epidural adhesions by using a stiff type guide wire and 4F vascular catheter is an effective method in the treatment of FBSS and it has a value in clinical application.

**Key words**: Failed Back Surgery Syndrome. Tissue Adhesions. Epidural Space. Back Pain.

**RESUMO**

**OBJETIVO:** Investigar a eficácia e a exequibilidade da aplicação da lise percutânea de aderências epidurais na síndrome pós-laminectomia usando um fio-guia tipo Stiff e um cateter vascular 4F.

**MÉTODOS:** Noventa e dois pacientes com síndrome pós-laminectomia foram randomizados em dois grupos: grupo controle (tratado somente com injeção de dexametazona) e grupo lise percutânea de aderências epidurais. Escores de escala visual analógica (VAS) e avaliação terapêutica foram observadas no pré-operatório, no sétimo dia de pós-operatório, um mês e seis meses de pós-operatório.

**RESULTADOS:** Escores VAS para dor foram significantemente reduzidos em ambos os grupos aos sete dias. Os escores VAS foram mais altos no grupo controle comparado ao da lise epidural nos tempos de um mês e seis meses. Entretanto, não há diferença estatística nos escores VAS de um mês e seis meses quando comparados, respectivamente, àqueles de antes da operação do grupo controle. Pacientes com a lise epidural relataram taxa de eficiência de 50%. Nos pacientes do grupo controle foi 5,26%, havendo diferença estatística entre os dois grupos.

**CONCLUSÃO:** A lise percutânea de aderências epidemias usando um fio-guia tipo Stiff e um cateter vascular 4F mostrou-se um método efetivo no tratamento de FBSS e tem valor na aplicação clínica.

**Descritores:** Síndrome Pós-Laminectomia. Aderências Teciduais. Espaço Epidural. Dor nas Costas.

## Introduction

Failed back surgery syndrome (FBSS) is clinically defined as persistent or recurrent pain, mainly in the lower back and/or legs, even after previous anatomically successful spinal surgery[1]. The FBSS is a heterogeneous entity that may result from incorrect initial diagnosis, poor patient selection incomplete decompression, decompression at the wrong level, recurrent disk hernination, segmental spinal instability, facet joint disease, permanent nerve root damage, epidural fibrosis, or arachnoiditis[2-4]. The contribution of fibrosis as the origin of low back pain has been debated. In patients who have undergone prior laminectomies, there is always some degree of perineural fibrosis. Although scar tissue itself is never tender, the nerve root is frequently very sensitive. Kuslich[5] concluded that the presence of scar tissue compounded pain associated with the nerve root by fixing it in one position and thus increasing the susceptibility of the nerve root to tension or compression. Moreover, these researchers concluded that," Sciatica can only be produced by direct pressure or stretch on the inflamed, stretched, or compressed nerve root. No other tissues in the spine are capable of producing leg pain". Stolkerr *et al.*[6] contended that innervated structures are the only originators of pain.

Treatment of FBSS is a challenge, as conservative therapies (eg.opiates, antiepileptic drugs such as gabapentin, local anesthetics) and repeated back surgery are often unsuccessful in providing adequate pain relief[7]. At present, conservative treatments have a poor effect, and a reoperation often causes a major injury with an ineffective curative effect. To find a minimally invasive treatment with an effective curative effect becomes a major issue. The purpose of the current study was to investigate the efficacy and the feasibility of application of percutaneous lysis of epidural adhesions in FBSS using a stiff type guide wire and 4F vascular catheter.

## Methods

The study was approved by the local Ethics Committee (our hospital's ethics committee and all patients signed informed consent). Clinical subjects were 76 patients with FBSS from May 2006 to August 2009(containing 44 male, 32 female, age ranged from 42 to 64 years old) after a lumbar discectomy with a course from 6 to 24 months.

*Diagnostic criteria*

After a lumbar disc herniation surgery, patients still have lumbocrural pain symptoms, numbness of skin in innervation areas, two of the four neurological signs including a small angle of straight leg raising, muscle atrophy, hypoesthesia or hyporeflexia.

*Inclusive criteria*

Inclusion criteria were a history of lumbar surgery of at least six months duration in the past; patients over the age of 18 years; patients with a history of chronic fuction-limiting lower extremity pain with or without low back pain of at least six months duration (post-surgery); and patients who are competent to understand the study protocol and provide voluntary, written informed consent and participate in outcome measurements. Inclusion criteria also included no evidence of facet joint pain and failure to improve substantially with conservative management including but not limited to physical therapy, chiropractic manipulation, exercised, drug therapy.

*Exclusive criteria*

Facet joints (those who tested positive for facet joint mediated pain), uncontrollable as sole pain generators, unstable or heavy opioid use (400mg of morphine equivalents daily), uncontrolled psychiatric disorders, uncontrolled medical illness, any conditions that could interfere with the interpretation of the outcome assessments, pregnant or lactating women, and patients with a history or potential for adverse reactions to local anesthetic, steroids, or hypertonic sodium chloride solution.

*Randomization*

From a total of 92 patients, 46 patients will be randomly assigned into each group. Randomization was performed by computer generated random allocations sequence by simple randomization. The operating room nurse assisting with the drugs appropriately. Participants were invited to enroll in the study if they met inclusion criteria. One of the four nurses assigned as coordinators of the study enrolled the participants and assigned participants to their respective groups. Participants and those administering the interventions were blinded to the group assignment. The blinding was assured by mixing the patients with other patients receiving routine treatment and not informing the physician performing the procedure of the inclusion of the patients in the study.

All the patients completing six months follow-up were selected by the statistician who was not participating in provision of patient care. The unblinding results were not disclosed to either

the treating physician or other participants or patients. In this manner, the nature of blinding was not interrupted. Thirty-eight consecutive patients per group were selected for data analysis and this report.

*Treatment*

Localization performed by C-arm perspective and then a 4F vascular catheter (Terumo Corporation, Japan) induced by a stiff type guide wire was punctured through hiatus sacralis to the lesion site (anterior epidural space) of patients in prone position in epidural lysis group. There was no blood or cerebrospinal fluid in pumping-back and the total spinal anesthesia test was negative. 5 ml of contrast agent iohexol was injected to the anterior epidural space. The duct opening direction was adjusted according to the developing situation of the contrast agent in the anterior epidural space, 50 to 80 ml saline was quickly inject. Generally, a successful percutaneous lysis of epidural adhesions is accompanied with the disappearance of filling defects, and a good developing of contrast agent with typical bilateral signs on lateral film in the epidural anterior space. After percutaneous lysis, patients were given 10 mg dexamethasone. After the withdrawal of the duct, the local skin was covered with a piece of aseptic compress. In addition, patients were asked to lie in bed for at least one day. By contrast, Patients in control group received a puncture to the epidural anterior space for angiography and an injection of 10 mg dexamethasone instead of percutaneous lysis of epidural adhesions.

*Follow-up*

Efficacy was assessed in clinics before the operation, seven days, one month and six months after the operation. Each patient underwent a standard physical examination and was asked to complete a 100mm visual analogue scale (VAS) questionnaire, in which 0 mm represented no pain and 100mm the worst imaginable pain, for low back pain and leg symptoms on movement during activities of daily living. Efficacy was valued using the modified MaCnab[9] evaluation standard, e.g., excellent: disappearance of pain and numbness symptoms, without any motor dysfunction; good: disappearance of the most primary symptoms, occasional pain; common: symptoms improvement, pain, and inability to participate in daily work; bad: non-improvement or aggravation of symptoms, inability to participate in daily work. The treatment of the excellent and good cases was assessed to be effective.

Conservative therapy (physiotherapy, bracing, acupuncture) performed before epidural lysis was continued during the 6-month follow-up period in each patients. When patients developed signs of progressive motor disorders, motor weakness in the lower extremities and bladder dysfunction, reoperation was considered. Any potential complications (infection, rash, reaction, subarachnoid blockade) were also evaluated at each visit.

*Data collection and statistical analysis*

Study population was analyzed on an intention-to-treat basis. The sample size calculation was based on the primary efficacy variable with an assumption of a 1:1 randomization ration of control group and epidural lysis group .Assuming a standard deviation of 1.5 and normally distributed responses, a sample size of 25 randomized patients per group was calculated to provide 90% power to detect a difference of 1.25 in the end point in the two groups, with 2-sided testing at the 0.05 level. Assuming a 30% patient dropout rate, a total sample size of about 35 randomized patients per group was required to demonstrate significant difference in efficacy between the two groups. The null hypothesis for the study was that here is no significant difference between the two groups in reducing the 11-point pain intensity score in patients with FBSS.

Each treatment arm was assessed by comparing the results to the baseline results using repeated measures ANOVA. Between-groups comparison was done by using ANOVA. Global impression of therapy was analyzed using Chi-square test. A 2-sided p value of less than 0.05 was considered statistically significant.

**Results**

There are 16 patients lose connection, the study group consisted of 21 males and 17 females with a mean age of 59.2 and the control group consisted of 23 males and 15 females with a mean age of 58.4. There was no statistical difference in regard to age, gender, weight and VAS scores between the groups ($p>0.05$) (Table 1).

**TABLE 1** - Demographic characteristics at inclusion (n=38).

| Variable | | Control group | Epidural lysis group |
|---|---|---|---|
| Age (yeas) | Mean(SD) | 58.4（12.3） | 59.2(11.8) |
| Male (%） | | 60.5% | 55.26% |
| Weight(kg) | Mean(SD) | 68.3(11.2) | 65.5(11.7) |
| time since PAIN in months | Mean(SD) | )12.6 (4.8) | 13.2(4.9) |
| Pain VAS score | Mean(SD) | 6.14(1.41) | 5.93(1.43) |

SD: standard deviation

VAS scores: In two groups, VAS scores for pain were significantly reduced in both the groups at seven days (5.47, 3.5). The VAS scores were 6.00, 6.21 in controlled group at one month, six months. The VAS scores were 3.55, 3.71 in epidural lysis group at one month, six months, there was a statistical difference between two groups (p=0.000) (Table 2).

**TABLE 2** - VAS scores before operation, seven days, one month, six months post operation.

| | Before operation | seven days | one month | six months |
|---|---|---|---|---|
| Control group | 7.03±1.24 | 5.47±2.17 | 6.00±1.74 | 6.21±1.64 |
| Epidural lysis group | 6.95±1.25 | 3.50 ±2.28 | 3.55±2.16 | 3.71±1.96 |

Two groups at baseline:t=0.276 p=0.783
Two groups at one month:t=0.0525 p=0.000
Two groups at one month:t=5.432 p=0.000
Two groups at three months:t=6.024 p=0.000
Control group before and seven days after treatment:p=0.000
Control group before and one month after treatment:p=0.000
Control group before and six month after treatment:p=0.000
Treatment group before and seven days after treatment:p=0.000
Treatment group before and one month after treatment:p=0.000
Treatment group before and six month after treatment:p=0.000

The six patients in epidural lysis group who the lysis failed without any significant change in epidural anterior space show no change in VAS scores.
Patients on epidural lysis reported clinical effectiveness at 6 months as excellent, good, common, bad in 8, 11, 7, 12, excellent and good rate was 50%. Patients on control were 0,2,17,19,5.26%,and there was a statistical difference between two groups (p<0.05) (Table 3).

**TABLE 3** - Effect standard of Macnab lumbar disease six months after the treatment.

| | Excellent | Good | Common | Bad | Excellent and good rate |
|---|---|---|---|---|---|
| Control group | 0 | 2 | 17 | 19 | 5.26% |
| Epidural lysis group | 8 | 11 | 7 | 12 | 50.00% |

*p*=0.000

Table 4 illustrates opioid intake between both groups.

**TABLE 4** - Daily opioid (morphine equivalents) before operation, seven days, one month, six months post operation.

| | Before operation | seven days | one month | six months |
|---|---|---|---|---|
| control group | 64.74±23.91 | 43.16±24.84 | 51.05±21.15 | 51.58±22.12 |
| epidural lysis group | 65.26±25.76 | 32.63±22.50 | 32.63±22.50 | 31.84±21.29 |

Two groups at baseline:t=0.092 p=0.927
Two groups at one month:t=1.936 p=0.057
Two groups at one month:t=3.763 p=0.000
Two groups at three months:t=3.963 p=0.000
Control group before and seven days after treatment:p=0.001
Control group before and one month after treatment:p=0.000
Control group before and six months after treatment:p=0.000
Treatment group before and seven days after treatment:p=0.000
Treatment group before and one month after treatment:p=0.000
Treatment group before and six months after treatment:p=0.000

There was no significant difference between two groups at baseline. There were significant reductions in opiod intakeat all follow-up periods in two groups compared to baseline. There were significant difference in opiod intake at all follow-up periods between two groups (p=0.000).

All the patients complete the treatment with a success rate of 100% of epidural anterior space tube indwelling. Varying degrees of adhesions were observed in all patients when performing epidural anterior space angiography. There was contrast agent surrounding neurons in form of Christmas tree and filling defects of contrast agent at adhesion segments in the epidural anterior space (Figure 1).

**FIGURE 1** - Before lysis of epidural adhesions.

There was contrast agent surrounding neurons in form of Christmas tree and filling defects of contrast agent at adhesion segments in the epidural anterior space.

After lysis of epidural adhesions by an injection of saline under pressure, filling defects disappeared, contrast agent was well developed in the epidural anterior space with typical bilateral signs on lateral film (Figure 2).

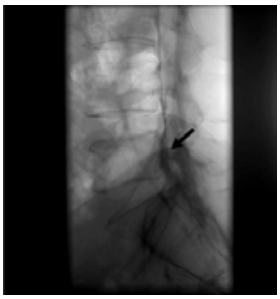

**FIGURE 2** - After lysis of epidural adhesions.

After lysis of epidural adhesions by an injection of saline under pressure, filling defects disappeared, contrast agent was well developed in the epidural anterior space with typical bilateral signs on lateral film.

The lysis failed in six cases without any significant change in epidural anterior space angiography all the time or any nerve injury complication.There were no instances of infection, rash, arachnoiditis, paralysis, weakness, bladder disturbances, or other serious complications.

**Discussion**

Epidural injection for managing FBSS is one of the most commonly performed interventions in the United States with exponential growth and geographic variations[9,10]. Epidural neuroplasty (lysis of epidural adhesions) is an interventional technique that was developed at Texas Tech Health Sciences Pain Center in 1989. When the technique of epidural neuroplasty (lysis of epidural adhesions) was first developed, the catheter was inserted into the posterior epidural space. As more and more procedures were performed, it was noted that the posterior epidural space was difficult to access in some patients who had undergone surgical procedures for diagnostic or radicular pain. This was more likely due to scar tissue from the previous surgery. In 1996, the technique for catheter insertion was changed to directing the catheter into the anterior epidural space. The catheter needed to be directed towards the anterior epidural space at the level of the S3 nerve root on the affected side for caudal neuroplasty. It also required the open end of the epidural needle to be directed anterolateral after insertion through the sacral hiatus. Percutaneous epidural adhesiolysis has been employed in interventional pain management in the management of chronic, refractory low back and lower extremity pain with the purpose of eliminating scar tissue and assuring the delivery of high concentrations of injected drugs to targeted areas[11,12].

Percutaneous lysis of epidural adhesions using PK needle, Racz catheter and hypertonic saline was reported by Racz. A good therapeutic effect was obtained in patients with lower back pain. Due to the catheter used with a steel wire, however, there are some disadvantages e.g., difficulty in reaching the lesion site, break-off, and breakthrough of epidural to subarachnoid by mistake. The most common and worrisome complications of neural blockade in the lumbar spine are related to dural puncture, spinal cord compression, catheter shearing, infection, steroids, hypertonic saline and hyaluronidase. Unintended subarachnoid or subdural puncture with injection of local anesthetic or hypertonic saline is one of the major complications of the procedure. Hypertonic saline injected into the subarachnoid space has been reported to cause cardiac arrhythmias, myelopathy, paralysis, and loss of sphincter control[13,14]. This study is aimed at investigating efficacy and feasibility of application of percutaneous lysis of epidural adhesions in FBSS using a stiff type guide wire and 4F vascular catheter.

In this study, varying degrees of adhesions were observed in all patients when performing epidural anterior space angiography. There was contrast agent surrounding neurons in the form of a Christmas tree and filling defects of contrast agent at adhesion segments in the epidural anterior space. After lysis of epidural adhesions by an injection of saline under pressure, filling defects disappeared, contrast agent was well developed in the epidural anterior space with typical bilateral signs on lateral film. The lysis failed in three cases without any significant change in epidural anterior space angiography all the time. The failure probably correlated with a long course and serious adhesions. Using C-arm perspective, a 4F vascular catheter was punctured through hiatus sacralis to the epidural anterior space induced by a stiff type guide wire. The guide wire and catheter have the advantage of a good flexibility and torque, plasticity, low surface friction coefficient. There is no danger of breakthrough of epidural or damage of nerve root. The direction of the catheter can be regulated to ensure it reaches the epidural anterior space.

Some epidurography showed fibrosis or adhesions at the suspected narrowing of the posterior epidural space. In these cases

slow volumes of fluid injection can induce transient neurological symptoms, such as headache or hypoacusia. Some authors have described visual impairment and retinal haemorrhage after epidural fluid injection[15], but we have not found any case in our study.

This study suggested that VAS scores of patients in control group decreased. The result probably correlated with epidural use of dexamethasone. The effective therapeutic effect for patients of one month and six months patients in epidural lysisgroup was significantly higher than that of control group, indicating that lysis of epidural adhesions can provide patients a long-term effect. The higher therapeutic effect correlated smaller groups and selection of patients (patients with a serious lumbar instability, osteoporosis, spinal stenosis or after operation of multiple section herniation were excluded).

## Conclusions

Lysis of epidural adhesions relieves oppression on the nerve and dural sac in patients with FBSS to obtain an effective therapeutic effect. It is a simple, safe and effective treatment without any adverse reaction. However, when considering lysis of epidural adhesions by using a stiff type guide wire and 4F vascular catheter as a treatment, the type of patient and the long term effect of the treatment needs further study.

## References


1. Van Buyten JP. Neurostimulation for chronic neuropathic back pain in failed back surgery syndrome. J Pain Symptom Manage. 2006;4(31):S25-9.
2. Rodrigues FF, Dozza DC, de Oliveira CR, de Castro RG. Failed back surgery syndrome. Arq Neuropsiquiatr. 2006;64(3-B):757-61.
3. Trescot AM, Chopra P, Abdi S, Datta S, Schultz DM. Systematic review of effectiveness and complications of adhesiolysis in the management of chronic spinal pain: an update. Pain Physician. 2007;10:129-46.
4. Manchikanti L, Manchukonda R, Pampati V, Damron KS, McManus CD. Prevalence of facet joint pain in chronic low back pain in postsurgical patients by controlled comparative local anesthetic bllocks. Arch Phys Med Rehabil. 2007;88:449-55.
5. Annertz M, Jonsson BS, Tromqvist B, Holtas S. No relationship between epidural fibrosis and sciatica in the lumbar postdisectomy syndrome. A study with contras-enhanced magnetic resonance imaging in symptomatic and asymptomatic resonance patients. Spine. 1995;4:449-53.
6. Stolker RJ, Vervest ACM, Groen GJ. The management of chronic spinal pain by blockades: a review. Pain.1994;58:1-20.
7. Hagen KB, Jamtvedt G, Hilds G, Winnem MF. The update Cochrane review of bed rest for low back pain and sciatica. Spine. 2005;30:542-6.
8. Gerszten PC, Moossy JJ, Flickinger JC, Wekch WX. Low-dose radiotherapy for the inhibition of peridural fibrosis after reexploratory nerve root decompression for postlaminectomy syndrome. J Neurosurg. 2003;99:271-7.
9. Macnab I. Negative disc exploration. An analysis of the causes of nerve-root involvement in sixty-eight patients. J Bone Joint Surg Am. 1971;53(5):891-903.
10. Manchikanti L, Singh V, Cash KA, Pampati V, Datta S. Preliminary results of randomized, equivalence trial of fluoroscopic caudal epidural injections in managing chronic low back pain: Part 3--Post surgery syndrome. Pain Physician. 2008;11:817-31.
11. Huntoon MA, Burgher AH. Back to the future: the end of the steroid century? Pain Physician. 2008;11:713-6.
12. Veihelmann A, Devens C, Trouiller H, Birkenmaier C, Gerdesmeyer L, Refior HJ. Epidural neuroplasty versus physiotherapy to relieve pain in patients with sciatica: a prospective randomized blinded clinical trial. J Orthop Science. 2006;11:365-9.
13. Racz GB, Heavner JE, Trescit A. Percutaneous lysis of epidural adhesions - evidence for safety and efficacy. Pain Pract. 2008;8:277-86.
14. Anderson SR, Racz GB. Heavner J. Evolution of epidural lysis of adhesions. Pain Physician. 2000;3:262-70.
15. Gill JB, Heavner JE. Visual Impairment following epidural fluid injections and epiduroscopy: a review. Pain Med. 2005;6:367-74.



**Correspondence:**
Prof. Ni jia-xiang
Department of Pain, Xuanwu Hospital
Capital Medical University
Xuanwu District, Beijing 100053, China
Tel./Fax:+86-0851-5625756
ni_jiaxiang@163.com



Received: November 10, 2011
Review: January 11, 2012
Accepted: February 14, 2012
Conflict of interest: none
Financial source: none

[1]Research performed at Department of Pain, Xuanwu Hospital, Capital Medical University, Xuanwu District, Beijing, China.